

REVIEW ARTICLE

Julie R. Ingelfinger, M.D., *Editor*

Mast Cells, Mastocytosis, and Related Disorders

Theoharis C. Theoharides, Ph.D., M.D., Peter Valent, M.D., and Cem Akin, M.D., Ph.D.

MAST CELLS, WHICH ARE PRESENT IN MOST TISSUES, MATURE IN SITU FROM hematopoietic progenitors and acquire unique features of local effector cells. These features vary, depending on the tissue microenvironment. This article provides an overview of recent developments concerning the physiology and pathobiology of mast cells. We discuss current diagnostic and therapeutic approaches to mast-cell disorders, with an emphasis on mastocytosis.

PHYSIOLOGY AND PATHOPHYSIOLOGY OF MAST CELLS

Mast cells develop from hematopoietic progenitors in response to stem-cell factor (KIT ligand), which is the ligand of the CD117 transmembrane tyrosine kinase receptor, encoded by *KIT*. CD117 regulates the growth, migration, survival, and effector functions of mast cells. Progenitors subsequently migrate from the blood into various tissues, including the skin, lungs, and mucosal interfaces, where they acquire their tissue-specific phenotype. The phenotype is influenced by the local microenvironment, especially blood vessels and nerve endings.¹

Mast cells, which are major effector cells of allergic reactions, are activated through exposure to an antigen (allergen) that cross-links allergen-specific IgE, which is already bound to the high-affinity Fc epsilon receptor 1 (FcεRI).² Mast cells can also be activated by many other triggers (Fig. 1), including anaphylatoxins (C3a and C5a), aggregated IgG, certain drugs, venoms, and physical stimuli (pressure and temperature changes), as well as cytokines and neuropeptides such as corticotropin-releasing hormone, neurotensin,³ stem-cell factor,⁴ and substance P^{5,6} (Fig. S1 in the Supplementary Appendix, available with the full text of this article at NEJM.org). Mast cells express receptors for diverse ligands,⁷ including toll-like receptors that can be activated by bacterial and viral products.⁸ Mast-cell activation can be enhanced by stem-cell factor and interleukin-33, which augment allergic activation⁹ and, in synergy with substance P, induce the release of vascular endothelial growth factor (VEGF).⁵ Stem-cell factor and interleukin-33 act as “sensors of cell injury.”¹⁰ Interleukin-33 requires costimulation with stem-cell factor for maximal cytokine release.¹¹

Allergic activation of mast cells leads to degranulation (see the video, and Fig. S2 in the Supplementary Appendix) and secretion of numerous vasoactive and proinflammatory mediators that are thought to contribute to the multiple symptoms observed in patients (Fig. 1).⁶ Preformed molecules stored in secretory granules include histamine, serotonin, proteases (e.g., tryptase, chymase, and carboxypeptidase), and tumor necrosis factor (TNF)¹²; TNF then participates in T-cell activation.¹³ In addition, mast cells secrete mitochondrial DNA, which carries out autocrine and paracrine stimulatory actions.¹⁴ Mast cells also release exosomes¹⁵ that are considered to be capable of delivering DNA and microRNAs to other cell types.¹⁶ Mast cells release newly synthesized leukotrienes, prostaglandins, and platelet-activating factor, as well as many cytokines (including interleukin-6, interleukin-9, interleukin-13, and TNF) and chemokines (CXCL8, CCL2, and CCL5). Experimental data show that mast cell–derived

From the Molecular Immunopharmacology and Drug Discovery Laboratory, Department of Integrative Physiology and Pathobiology, and Department of Internal Medicine, Tufts University School of Medicine, Tufts Medical Center (T.C.T.), and Mastocytosis Center, Brigham and Women's Hospital, Department of Medicine, Harvard Medical School (C.A.) — both in Boston; and the Department of Internal Medicine I, Division of Hematology and Hemostaseology and Ludwig Boltzmann Cluster Oncology, Medical University of Vienna, Vienna (P.V.). Address reprint requests to Dr. Theoharides at the Department of Integrative Physiology and Pathobiology, Tufts University School of Medicine, 136 Harrison Ave., Suite J304, Boston, MA 02111, or at theoharis.theoharides@tufts.edu.

N Engl J Med 2015;373:163-72.

DOI: 10.1056/NEJMra1409760

Copyright © 2015 Massachusetts Medical Society.



A video showing real-time activation of a mast cell is available at NEJM.org

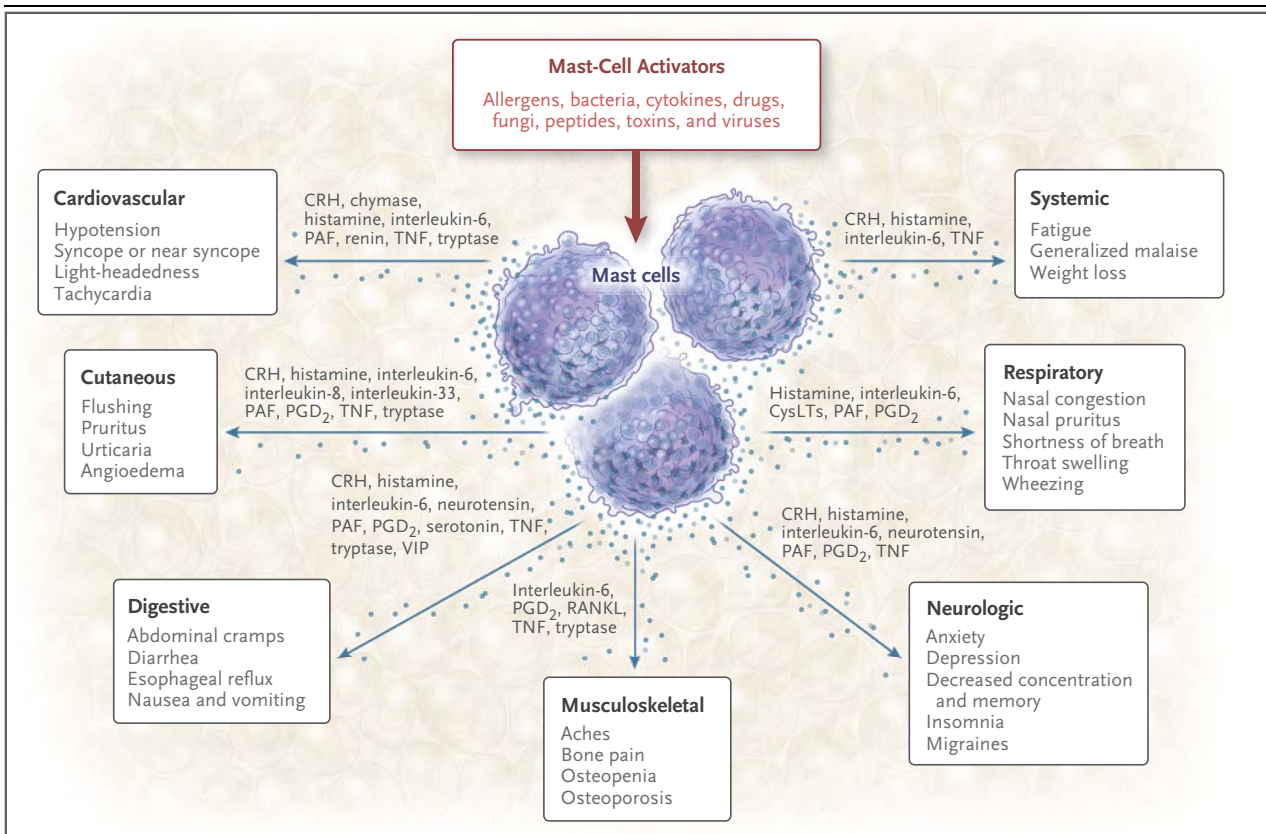


Figure 1. Clinically Relevant Mediators Released from Mast Cells and Putative Effects.

The most clinically relevant mediators released from mast cells, the corresponding organs and systems, and potential associated symptoms are shown. CRH denotes corticotropin-releasing hormone, CysLTs cysteinyl leukotrienes, PAF platelet-activating factor, PGD₂ prostaglandin D₂, RANKL receptor activator of nuclear factor- κ B ligand, TNF tumor necrosis factor, and VIP vasoactive intestinal peptide.

interleukin-6 and transforming growth factor β can induce the development of Th-17 cells through dendritic-cell maturation.¹⁷ Furthermore, interleukin-17 is secreted by mast cells themselves.¹⁸

Mast cells can secrete some mediators selectively.¹⁹ For example, one study²⁰ showed that they secrete interleukin-6 in response to interleukin-1; another study²¹ showed that they secrete VEGF in response to corticotropin-releasing hormone. Corticotropin-releasing hormone acts synergistically with neurotensin to augment VEGF release, increasing skin vascular permeability.³

Emotional stress is the most common trigger of symptoms in patients with systemic mastocytosis.²² The mechanism is incompletely delineated, though some data suggest that corticotropin-releasing hormone, secreted under stress, activates mast cells. For example, one patient whose symptoms worsened with stress had elevated serum corticotropin-releasing hormone levels, and her bone marrow mast cells expressed receptors for

this hormone.²³ Even though neuropsychiatric symptoms appear to be more common in patients with mastocytosis than in the general population,²⁴ the exact contribution of mast cells in the brain remains elusive.

Taken together, available data suggest that mast cells are capable of releasing a panoply of molecules that may participate in many physiologic and pathologic processes such as innate immunity,¹ autoimmunity,²⁵ and neuroinflammation,⁶ but they may also have immunomodulatory²⁶ and antimicrobial⁸ functions.

MAST CELLS AND HUMAN DISORDERS

The diagnosis and treatment of mast-cell disorders are challenging because of the complexity of the symptom profile and the frequent presence of co-existing conditions in patients with these disorders (Table 1). Symptoms that have been associated

with mast-cell disorders are protean and include flushing, hives, urticaria, angioedema, itching, nasal congestion, shortness of breath, chest tightness,²⁷ tachycardia, hypotension or hypertension, fatigue, musculoskeletal pain, osteoporosis, nausea, vomiting, diarrhea,²⁸ migraines, and neurologic problems²⁹ such as difficulty concentrating, loss of memory,³⁰ and other neuropsychiatric issues²⁴ (Fig. 1).

Traditionally, mast cells were considered to be reactive to a variety of external factors such as allergens or other inflammatory or physical stimuli. However, knowledge of a more active role of mast cells has emerged, largely owing to observations in patients with disorders that involve clonal expansion of mast cells in the bone marrow. In particular, anaphylaxis to stings from insects of the order Hymenoptera and episodes of idiopathic anaphylaxis appear more likely to develop in patients with systemic mastocytosis (see below) than in the general population.³¹⁻³³

Sensitive assays to detect *KIT* mutations and to characterize the mast-cell phenotype by means of flow cytometry and immunohistochemical analysis³⁴ have been used to identify a subgroup of patients who previously had received a diagnosis of idiopathic anaphylaxis, and these assays have revealed evidence of clonal mast-cell populations in their bone marrow.³³ Such associations suggest that intrinsic (molecular) defects in mast cells may regulate susceptibility to anaphylaxis. The magnitude of response to IgE-dependent stimuli may be greater when the burden of mast cells in such patients is high. However, since there is not a direct correlation between the mast-cell burden and the actual risk of anaphylaxis,^{32,35} there may be additional explanations.

It is not known how the presence of clonally expanded mast cells might lead to increased susceptibility to anaphylactic reactions to certain triggers, such as hymenoptera venom. Perhaps perivascular mast cells can rapidly deliver vasoactive mediators into the intravascular compartment, venom may have direct effects on clonal mast cells, or dysregulated signal-transduction pathways downstream of mutant *KIT* molecules may be involved in mast-cell activation.

Various disorders are associated with an increased number of mast cells, activation of mast cells, or both. On the basis of clinical findings, as well as on the histologic features and clonality of mast cells, these disorders are broadly divided into those defined by expansion of clonal mast cells

Table 1. Conditions That Can Mimic Mast-Cell Disorders.

Cardiac conditions
Coronary hypersensitivity (the Kounis syndrome)* Postural orthostatic tachycardia syndrome
Endocrine conditions
Fibromyalgia Parathyroid tumor Pheochromocytoma Carcinoid syndrome
Digestive conditions
Adverse reaction to food* Eosinophilic esophagitis* Eosinophilic gastroenteritis* Gastroesophageal reflux disease Gluten enteropathy Irritable bowel syndrome Vasoactive intestinal peptide–secreting tumor
Immunologic conditions
Autoinflammatory disorders such as deficiency of interleukin-1–receptor antagonist* Familial hyper-IgE syndrome Vasculitis*
Neurologic and psychiatric conditions
Anxiety Chronic fatigue syndrome Depression Headaches Mixed organic brain syndrome Somatization disorder Autonomic dysfunction Multiple sclerosis
Skin conditions
Angioedema* Atopic dermatitis* Chronic urticaria* Scleroderma*

* Localized mast-cell activation can occur.

(Table S1 in the Supplementary Appendix) and those defined by mast-cell activation. An individual patient may have evidence of both a clonal mast-cell disorder and coexisting mast-cell activation.

PRIMARY CLONAL MAST-CELL DISORDERS

Mastocytosis is defined by abnormal clonal mast-cell expansion and accumulation in various tissues, such as the bone marrow and skin.³⁶ The World Health Organization (WHO) classification of mastocytosis includes seven different categories (Table S1 in the Supplementary Appendix). The actual prevalence of mastocytosis is unknown, but an estimate from a recent population-based study is approximately 1 case per 10,000 persons.³⁷

CUTANEOUS MASTOCYTOSIS

The most common form of mastocytosis in children, cutaneous mastocytosis, is diagnosed in the first years of life. It is commonly characterized by multiple hyperpigmented macular or maculopapular lesions that become urticarial when rubbed or scratched (Darier's sign).³⁸ In most children with cutaneous mastocytosis, the condition resolves or improves by puberty. Three major variants of cutaneous mastocytosis have been defined — maculopapular mastocytosis (also termed urticaria pigmentosa), diffuse cutaneous mastocytosis, and mastocytoma of skin³⁸ (Table S1 in the Supplementary Appendix).

Patients with cutaneous mastocytosis do not fulfill the criteria for the diagnosis of systemic mastocytosis.³⁹ However, cutaneous mastocytosis is occasionally associated with symptoms such as gastrointestinal cramping or anaphylaxis, even in the absence of disease involving the bone marrow.⁴⁰ Such symptoms are generally triggered by physical irritation of the involved skin or by stress or exercise. They may also occur in association with fever.

Cutaneous mastocytosis is associated with gain-of-function *KIT* mutations in approximately 60 to 80% of cases.⁴¹ Children with typical cutaneous lesions usually do not require a bone marrow biopsy if hepatosplenomegaly, lymphadenopathy, or peripheral-blood abnormalities are absent⁴²; however, systemic mastocytosis often is present in adults with skin lesions. In contrast, skin lesions may be absent in many patients with aggressive systemic disease.

SYSTEMIC MASTOCYTOSIS

The categories of systemic mastocytosis, which is characterized by mast-cell infiltration of various internal organs (most commonly bone marrow), are indolent mastocytosis, aggressive mastocytosis, mastocytosis associated with a hematologic non-mast-cell-lineage disease,³⁹ and mast-cell leukemia (Table S1 in the Supplementary Appendix). Among patients with indolent systemic mastocytosis, which is the most common variant, life expectancy is similar to that in the general population.⁴³ Most such patients have mast-cell mediator-related symptoms.

Aggressive systemic mastocytosis, which is characterized by specific tissue damage associated with mast cells, is most commonly identified in the bone marrow, liver, gastrointestinal tract, and cortical bone. Portal hypertension and ascites,

malabsorption, cytopenias, and large osteolytic lesions with pathologic fractures may ultimately develop in these patients. Patients with systemic mastocytosis and associated hematologic disease often have evidence of an additional myeloproliferative or myelodysplastic syndrome. The diagnosis of mast-cell leukemia is based on the presence of more than 20% atypical mast cells in bone marrow–aspirate smears or more than 10% immature mast cells in the peripheral blood; bone marrow–biopsy specimens typically show a high-grade involvement (>50%) of the medullary space with sheets of atypical mast cells.

Almost all patients with indolent systemic mastocytosis and approximately 80% of all patients with systemic mastocytosis have a somatic “gain-of-function” mutation in *KIT*, most commonly in codon 816 (D816V), where a valine is substituted for an aspartate.^{44,45} The D816V mutation renders *KIT* constitutively active, independent of stem-cell factor, resulting in autophosphorylation, which leads to autonomous mast-cell differentiation and survival. The mutated *KIT* allele burden correlates with the subtype of systemic mastocytosis.⁴⁴ However, progression from indolent systemic mastocytosis to more aggressive forms is rare.

In a given patient, the *KIT* mutation may be restricted to mast cells or it may be present in other hematologic lineages,⁴⁶ in which case it is regarded as a risk factor for progression.⁴⁷ Mutations in addition to *KIT* D816V may be present in other genes such as *TET2* (tet methylcytosine dioxygenase 2) or *ASXL1* (additional sex combs–like 1), but their contribution to the pathogenesis of disease is not clear.

MAST-CELL ACTIVATION

Patients with increased numbers of mast cells, as is the case in systemic mastocytosis, may not always have symptoms of mast-cell activation. Conversely, mast-cell activation is often seen in patients in whom the mast-cell burden is normal, as in patients with allergic rhinitis⁴⁸ or those presenting with anaphylaxis in whom serum tryptase levels reportedly increase during the attack but later return to normal values.⁴⁹ However, mast-cell activation and severe anaphylactic reactions are more common in patients with systemic mastocytosis than in healthy controls. The symptoms may be subtle in a patient who has a less severe form of mast-cell activation. Serum tryptase levels that increase by 20% above the baseline level plus an

additional 2 ng per milliliter if measured within 4 hours after the onset of the acute event suggest mast-cell involvement. Other mast-cell mediators such as the urinary histamine metabolites and 11- β -prostaglandin F_{2 α} (11 β -PGF_{2 α}) may be potential biomarkers of mast-cell activation, since these are increased with mast-cell activation.⁵⁰

In some patients with primary severe mast-cell activation, there is evidence of mast-cell clonality (a *KIT* mutation or CD25+ mast cells) that may fulfill the diagnostic criteria for systemic mastocytosis.^{33,51,52} In other patients, there is evidence of clonal mast-cell expansion, but the criteria for systemic mastocytosis are not met and these patients are known to have monoclonal mast-cell activation,^{33,53} which is increasingly recognized in patients with hymenoptera-induced or idiopathic anaphylaxis. Reactive hyperplasia of nonclonal mast cells in the absence of mast-cell activation may be identified in tissue-biopsy specimens obtained from patients with chronic inflammation, thrombosis, or cancer.⁵⁴

DIAGNOSTIC TESTS

Figure 2 shows a diagnostic algorithm. We suggest that the total serum tryptase levels be measured in all patients with suspected mastocytosis of any severity.^{42,55} If the tryptase level is elevated during a symptomatic event, it should be measured again at least 24 hours after symptoms resolve. In the case of anaphylaxis, the basal tryptase level increases during the event and returns to the baseline level after the event (Fig. 2). If the basal tryptase level is also elevated, the likelihood of systemic mastocytosis is high.

For patients with unclear symptoms that are not attributable to another disease entity or for patients with slightly elevated serum tryptase levels, screening with highly sensitive polymerase-chain-reaction techniques for *KIT* D816V transcripts in peripheral-blood leukocytes^{44,56} has been introduced to the diagnostic algorithm for suspected mastocytosis. For patients in whom the *KIT* mutation is detected in peripheral blood, a bone marrow evaluation is indicated.

The diagnosis of systemic mastocytosis is based on the presence of one major and one minor criterion or three minor criteria established by the WHO.³⁹ The major criterion is multifocal clustering of mast cells (>15 mast cells per cluster) identified by means of tryptase immunohistochemical analysis (Fig. 3A), *KIT* immunohistochemical analysis

(Fig. 3B), or both in an extracutaneous organ, commonly the bone marrow.³⁹ Minor criteria include abnormal morphologic features of mast cells (e.g., spindle shapes with cytoplasmic projections and sometimes bilobed and multilobed nuclei), the presence of the *KIT* D816V mutation, expression of CD2 or CD25 on mast cells (Fig. 3B), and an increased basal serum tryptase level (≥ 20 ng per milliliter).³⁹

A bone marrow biopsy, which should be considered in all adult patients with typical skin lesions (Fig. 3C), is also recommended for patients with unexplained hypotensive episodes, syncope, or both, especially when basal or event-related serum tryptase levels are clearly elevated (Fig. 2).³⁹ A bone marrow biopsy and aspirate should also be considered in patients with even a slightly elevated serum tryptase level (11.5 to 20.0 ng per milliliter) if the patient has typical clinical findings such as unexplained osteoporosis (especially in male patients) or unexplained episodes of hypotensive syncope; splenomegaly, lymphadenopathy, or both; or blood-count abnormalities. In addition, measurement of total and allergen-specific serum IgE to rule out the presence of an allergic disease should be performed if a patient's history is suggestive of an allergic trigger (such as hymenoptera stings), regardless of the presence or absence of systemic mastocytosis.

Other entities may have overlapping symptoms. Therefore, serum gastrin, parathyroid hormone, and calcitonin levels should be considered to rule out gastrinoma, parathyroid tumors, or medullary thyroid tumors, respectively. Serum complement C4 and C1 inhibitor levels may be helpful in ruling out hereditary and acquired angioedema, but urticaria is absent in those conditions. In addition, 24-hour urinary levels of the metabolites of serotonin (5-hydroxyindoleacetic acid) and catecholamines (including vanillylmandelic acid) can be used to screen for carcinoid syndrome and pheochromocytoma, respectively.

TREATMENT APPROACHES

It is important for patients with mastocytosis to avoid substances and environments that may provoke mast-cell activation. If an acute anaphylactic episode occurs, it should be treated aggressively with intramuscular epinephrine (adrenaline) at a dose of 0.3 mg of 1:1000 solution in adults and 0.01 mg per kilogram of body weight in children, not to exceed a total dose of 0.3 mg. This treatment

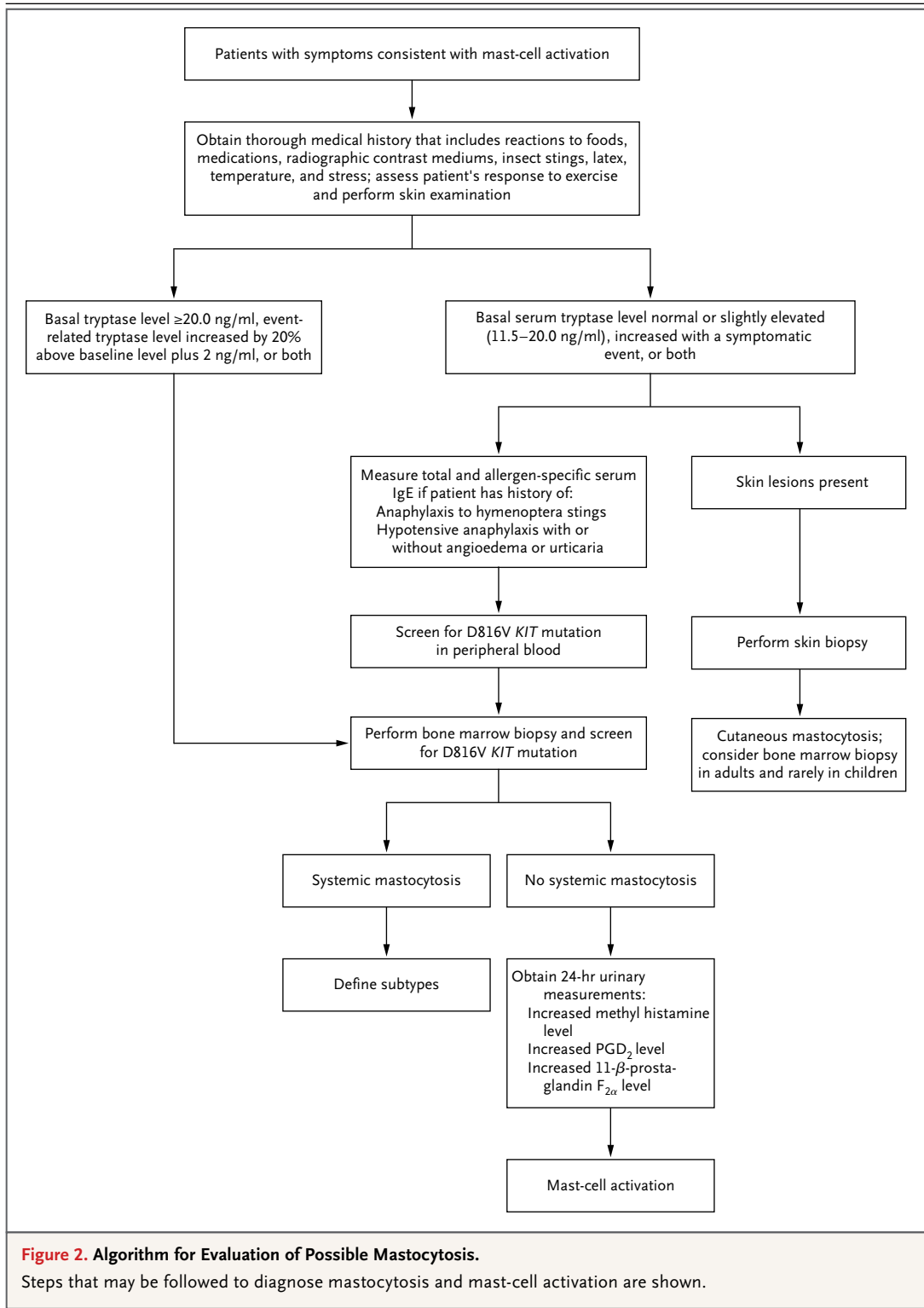


Figure 2. Algorithm for Evaluation of Possible Mastocytosis.

Steps that may be followed to diagnose mastocytosis and mast-cell activation are shown.

may be repeated twice within 5 to 15 minutes. Intravenous diphenhydramine (25 to 50 mg in adults and 1 mg per kilogram to a maximum dose of 40 mg in children) or glucocorticoids such as

methylprednisolone (which are often used as adjunctive treatment) at a dose of 1 mg per kilogram to a maximum dose of 125 mg in adults and 0.25 to 1 mg per kilogram, not to exceed 60 mg, in

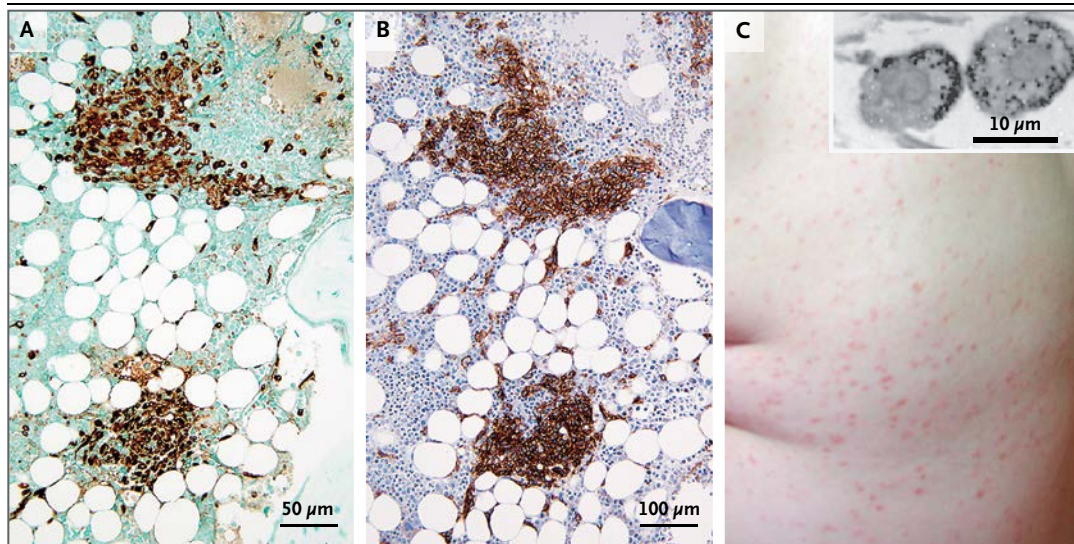


Figure 3. Photomicrographs of Bone Marrow–Biopsy Specimens Obtained from a Patient with Indolent Systemic Mastocytosis and Skin in a Patient with Urticaria Pigmentosa.

Panel A shows two clusters of mast cells stained light brown with anti-CD25 antibody. Panel B shows another two clusters of mast cells stained with an antitryptase antibody. Images in Panels A and B are courtesy of Jason L. Hornick, M.D., Ph.D. Panel C shows the flank of a patient with diffuse urticaria pigmentosa; the insert shows a transmission electron micrograph of two skin mast cells obtained from a biopsy specimen of one urticaria pigmentosa lesion. Few intact (dark) secretory granules are located at the periphery, and the rest of the granules (light gray) have already secreted their contents (degranulated).

children may be administered according to published guidelines.⁵⁷ Systemic glucocorticoids do not have an immediate benefit, and some patients cannot receive them because of side effects.

DRUGS THAT INTERFERE WITH MAST-CELL SYMPTOMS

There is no treatment that results in permanent resolution of the skin lesions associated with cutaneous or systemic mastocytosis. Common symptoms of cutaneous or systemic mastocytosis are usually addressed through administration of non-sedating and longer-acting histamine (H_1)-receptor antagonists such as loratadine (starting dose in adults, 10 mg orally daily; 5 mg orally daily in children younger than 6 years of age; 10 mg orally daily in children 6 years of age or older), cetirizine (starting dose in adults, 5 to 10 mg orally daily; 2.5 mg orally daily in children younger than 6 years of age; 5 to 10 mg orally daily in children 6 years of age or older), and fexofenadine (starting dose in adults, 180 mg orally once daily with water; 15 mg orally twice daily with water in children 6 months to 2 years of age; 30 mg orally twice daily with water in children older than 2 to 12 years of age). Hydroxyzine (starting dose, 25 mg orally three times a day in adults; 50 mg orally daily in divided

doses [alternatively, 2 mg per kilogram orally, in divided doses every 6 to 8 hours, not to exceed 50 mg per day] in children younger than 6 years of age; 50 to 100 mg orally daily in divided doses in children 6 years of age and older) can also be used. Hydroxyzine is also an anxiolytic agent, and its sedation is usually reduced after daily administration.

The dual H_1 - and serotonin-receptor antagonist cyproheptadine (starting dose in adults, 4 mg orally three times daily; 2 mg orally two to three times daily, not to exceed 12 mg a day, in children 2 to younger than 6 years of age; 4 mg orally two to three times daily, not to exceed 16 mg a day, in children 6 to 14 years of age) may be considered for patients with diarrhea, flushing, or headaches. Histamine H_2 -receptor antagonists such as famotidine (starting dose in adults, 20 mg orally once or twice daily; 0.5 mg per kilogram two times daily, not to exceed 40 mg per dose, in children 1 to 16 years of age) and ranitidine (starting dose in adults, 150 mg twice daily; 4 to 10 mg per kilogram daily administered in two divided doses every 12 hours, not to exceed 300 mg orally daily, in children 1 month to 16 years of age) are also helpful in patients with gastrointestinal symptoms such as heartburn, nausea, abdominal cramping, and diarrhea.

Cysteine–leukotriene-receptor antagonists such as montelukast (10 mg orally daily in adults; 4 mg orally once daily in children younger than 6 years of age; 5 mg orally daily in children between 6 and 14 years of age) or the 5-lipoxygenase inhibitor zileuton may be useful when used in conjunction with H₁- and H₂-receptor antagonists.⁵⁸ Acetylsalicylic acid (81 to 325 mg orally once or twice daily in adults) may be beneficial in some patients who have flushing and angioedema (with high levels of urinary prostaglandin D₂ or 11β-PGF_{2α}) if the patient's ability to receive nonsteroidal antiinflammatory drugs without adverse effects is known. Tricyclic antidepressants (e.g., amitriptyline or doxepine) (25 to 100 mg orally daily depending on side-effect profile in adults) and prochlorperazine (5 to 10 mg orally three or four times daily in adults) may be useful because they have both histamine H₁-receptor antagonism and mast-cell inhibitory properties,⁵⁹ but sedation and weight gain decrease patient adherence.

Psoralen and ultraviolet A or narrow-band ultraviolet B therapy may alleviate itching and help fade lesions temporarily.⁶⁰ Topical glucocorticoids are generally not recommended, since the lesions typically involve large body-surface areas.

DRUGS THAT INTERFERE WITH MAST-CELL ACTIVATION

Ketotifen⁶¹ (1 to 2 mg orally twice daily in adults; 0.5 mg orally twice daily in children 6 months to 3 years of age; 1 mg daily in children 3 years of age or older) and rupatadine⁶² (10 mg orally twice daily in adults; 2.5 mg orally in children with a body weight of 10 to 25 kg; 5 mg orally daily in children with a body weight of 25 kg or more) are H₁-receptor antagonists, but they are also reported to have blocking effects on mast-cell activation. Disodium cromoglycate (cromolyn) (200 mg orally three or four times daily in adults; 100 mg orally three or four times daily in children between 2 and 12 years of age) reduces gastrointestinal symptoms,⁶³ though it is a weak *in vivo* inhibitor of mast-cell activation.^{64,65} The structure of cromolyn resembles that of the natural flavone luteolin and its more potent analogue, tetramethoxyluteolin, both of which have antiinflammatory actions and inhibit secretion of mast-cell mediators.⁶⁶ Case reports suggest that the anti-IgE monoclonal antibody omalizumab, which is approved for the treatment of asthma and chronic urticaria,⁶⁷ may prevent recurrent anaphylactic episodes.⁶⁸

DRUGS THAT INTERFERE WITH MAST-CELL PROLIFERATION AND SURVIVAL

Cytoreductive therapy is indicated in aggressive systemic mastocytosis and mast-cell leukemia, though data are lacking from large clinical trials. The tyrosine kinase inhibitor imatinib has been reported to reduce mast-cell burden in a small percentage of patients with systemic mastocytosis who lack the *KIT* D816V mutation.⁶⁹ *In vitro* studies have shown that the multikinase inhibitor PKC412 (midostaurin) inhibits the growth and survival of mast cells (including cells bearing *KIT* D816V) as well as IgE-dependent mast-cell activation.⁷⁰ The orally bioavailable Src-family and BCR-ABL inhibitor dasatinib is active against *KIT* D816V-expressing mast cells *in vitro*, although clinical findings have been largely disappointing.⁷¹

In small studies involving a subgroup of patients with aggressive systemic mastocytosis, the mast-cell burden and symptoms were reduced with 2-chloro-2'-deoxyadenosine (cladribine).^{72,73} Interferon alfa also reduces mast-cell growth and activation in some patients. Bone marrow transplantation has recently been reported in a small series of patients with advanced forms of mastocytosis.⁷⁴ Several drugs under development target various surface receptors, signaling molecules, or both, such as PI3 kinase, AKT, or the mammalian target of rapamycin (now known as sirolimus).⁷⁵

SUMMARY AND FUTURE DIRECTIONS

Pathologic conditions involving mast cells appear to be more common than once thought. The diagnosis and treatment of such disorders are challenging, given protean symptoms and the presence of coexisting conditions. In patients with severe symptoms or those with allergies to hymenoptera venom, the investigation of mast-cell monoclonality may provide the diagnosis. Identification and avoidance of triggers, including emotional or physical stress, may be helpful.

Most symptoms can be managed with histamine-receptor antagonists or other drugs that interfere with mast-cell mediators, along with blockers of mast-cell activation. Patients with aggressive mastocytosis may require additional drugs to interfere with the proliferation and survival of mast cells. Data are lacking to identify reliable biomarkers of mast-cell activation, signaling steps through which many triggers converge, drugs with dual inhibitory activity against mast-cell proliferation

and mast-cell activation, and methods for delivering drugs specifically to mast cells.

Dr. Theoharides reports receiving royalties from a patent (US 8,268,365 B2) related to an antiinflammatory composition for treating brain inflammation, licensed to Algonot (a portion of the proceeds is given to Tufts University under an agreement and another portion is given to to AutismFreeBrain, a nonprofit company for autism research). He also reports holding a patent (US 7,906,153 B2) related to mast cells, antiinflammatory agents, multiple sclerosis, central nervous system disorders, and a mixture of flavonoids and olive extracts, a patent (US 7,799,766 B2) related to the treatment of hormonally dependent cancers, and a patent (US 6,689,748 B1) related to a method of treating mast-cell activation–induced diseases with a proteoglycan that

is licensed to Algonot. Dr. Valent reports receiving grant support from Ariad Pharmaceuticals, Celgene, Bristol-Myers Squibb, Pfizer, Novartis, and Blueprint Medicines. Dr. Akin reports receiving consulting fees from Novartis, Patara Pharma, and Blueprint Medicines and royalties from a patent (WO2003065986 A2) related to the Laboratory of Allergic Diseases 2 mast-cell line. No other potential conflict of interest relevant to this article was reported.

Disclosure forms provided by the authors are available with the full text of this article at NEJM.org.

We thank Smaro Panagiotidou, M.A., for her graphic-design and word-processing skills and Philip W. Askenase, M.D. (Yale University), Valerie M. Slee, R.N., and Julia M. Stewart, R.N. (both from the Mastocytosis Society, www.tmsforacure.org), for providing comments on an earlier version of the manuscript.

REFERENCES

- Galli SJ, Borregaard N, Wynn TA. Phenotypic and functional plasticity of cells of innate immunity: macrophages, mast cells and neutrophils. *Nat Immunol* 2011;12:1035-44.
- Rivera J, Fierro NA, Olivera A, Suzuki R. New insights on mast cell activation via the high affinity receptor for IgE. *Adv Immunol* 2008;98:85-120.
- Donelan J, Boucher W, Papadopoulos N, et al. Corticotropin-releasing hormone induces skin vascular permeability through a neurotensin-dependent process. *Proc Natl Acad Sci U S A* 2006;103:7759-64.
- Gagari E, Tsai M, Lantz CS, Fox LG, Galli SJ. Differential release of mast cell interleukin-6 via c-kit. *Blood* 1997;89:2654-63.
- Theoharides TC, Zhang B, Kempuraj D, et al. IL-33 augments substance P-induced VEGF secretion from human mast cells and is increased in psoriatic skin. *Proc Natl Acad Sci U S A* 2010;107:4448-53.
- Theoharides TC, Alysandratos KD, Angelidou A, et al. Mast cells and inflammation. *Biochim Biophys Acta* 2012;1822:21-33.
- Migalovich-Sheikhet H, Friedman S, Mankuta D, Levi-Schaffer F. Novel identified receptors on mast cells. *Front Immunol* 2012;3:238.
- Abraham SN, St John AL. Mast cell-orchestrated immunity to pathogens. *Nat Rev Immunol* 2010;10:440-52.
- Fux M, Pecaric-Petkovic T, Odermatt A, et al. IL-33 is a mediator rather than a trigger of the acute allergic response in humans. *Allergy* 2014;69:216-22.
- Enoksson M, Lyberg K, Möller-Westerberg C, Fallon PG, Nilsson G, Lunderius-Andersson C. Mast cells as sensors of cell injury through IL-33 recognition. *J Immunol* 2011;186:2523-8.
- Drube S, Heink S, Walter S, et al. The receptor tyrosine kinase c-Kit controls IL-33 receptor signaling in mast cells. *Blood* 2010;115:3899-906.
- Olszewski MB, Groot AJ, Dastyk J, Knol EF. TNF trafficking to human mast cell granules: mature chain-dependent endocytosis. *J Immunol* 2007;178:5701-9.
- Nakae S, Suto H, Kakurai M, Sedgwick JD, Tsai M, Galli SJ. Mast cells enhance T cell activation: importance of mast cell-derived TNF. *Proc Natl Acad Sci U S A* 2005;102:6467-72.
- Zhang B, Asadi S, Weng Z, Sismanopoulos N, Theoharides TC. Stimulated human mast cells secrete mitochondrial components that have autocrine and paracrine inflammatory actions. *PLoS One* 2012;7(12):e49767.
- Skokos D, Botros HG, Demeure C, et al. Mast cell-derived exosomes induce phenotypic and functional maturation of dendritic cells and elicit specific immune responses in vivo. *J Immunol* 2003;170:3037-45.
- Bryniarski K, Ptak W, Jayakumar A, et al. Antigen-specific, antibody-coated, exosome-like nanovesicles deliver suppressor T-cell microRNA-150 to effector T cells to inhibit contact sensitivity. *J Allergy Clin Immunol* 2013;132:170-81.
- Dudeck A, Suender CA, Kostka SL, von Stebut E, Maurer M. Mast cells promote Th1 and Th17 responses by modulating dendritic cell maturation and function. *Eur J Immunol* 2011;41:1883-93.
- Kenna TJ, Brown MA. The role of IL-17-secreting mast cells in inflammatory joint disease. *Nat Rev Rheumatol* 2013;9:375-9.
- Theoharides TC, Kempuraj D, Tagen M, Conti P, Kalogeromitros D. Differential release of mast cell mediators and the pathogenesis of inflammation. *Immunol Rev* 2007;217:65-78.
- Kandere-Grzybowska K, Letourneau R, Kempuraj D, et al. IL-1 induces vesicular secretion of IL-6 without degranulation from human mast cells. *J Immunol* 2003;171:4830-6.
- Cao J, Papadopoulou N, Kempuraj D, et al. Human mast cells express corticotropin-releasing hormone (CRH) receptors and CRH leads to selective secretion of vascular endothelial growth factor. *J Immunol* 2005;174:7665-75.
- Jennings S, Russell N, Jennings B, et al. The Mastocytosis Society survey on mast cell disorders: patient experiences and perceptions. *J Allergy Clin Immunol Pract* 2014;2:70-6.
- Theoharides TC, Petra AI, Stewart JM, Tsilioni I, Panagiotidou S, Akin C. High serum corticotropin-releasing hormone (CRH) and bone marrow mast cell CRH receptor expression in a mastocytosis patient. *J Allergy Clin Immunol* 2014;134:1197-9.
- Moura DS, Georgin-Lavialle S, Gaillard R, Hermine O. Neuropsychological features of adult mastocytosis. *Immunol Allergy Clin North Am* 2014;34:407-22.
- Rottem M, Mekori YA. Mast cells and autoimmunity. *Autoimmun Rev* 2005;4:21-7.
- Galli SJ, Grimbaldeston M, Tsai M. Immunomodulatory mast cells: negative, as well as positive, regulators of immunity. *Nat Rev Immunol* 2008;8:478-86.
- Kounis NG. Mechanisms of acute coronary syndromes. *N Engl J Med* 2013;369:883.
- Sokol H, Georgin-Lavialle S, Canioni D, et al. Gastrointestinal manifestations in mastocytosis: a study of 83 patients. *J Allergy Clin Immunol* 2013;132:866-73.
- Smith JH, Butterfield JH, Pardanani A, DeLuca GC, Cutrer FM. Neurologic symptoms and diagnosis in adults with mast cell disease. *Clin Neurol Neurosurg* 2011;113:570-4.
- Moura DS, Sultan S, Georgin-Lavialle S, et al. Evidence for cognitive impairment in mastocytosis: prevalence, features and correlations to depression. *PLoS One* 2012;7(6):e39468.
- Brockow K, Jofer C, Behrendt H, Ring J. Anaphylaxis in patients with mastocytosis: a study on history, clinical features and risk factors in 120 patients. *Allergy* 2008;63:226-32.
- van Anrooij B, van der Veer E, de Monchy JG, et al. Higher mast cell load decreases the risk of Hymenoptera venom-induced anaphylaxis in patients with mastocytosis. *J Allergy Clin Immunol* 2013;132:125-30.
- Akin C, Scott LM, Kocabas CN, et al. Demonstration of an aberrant mast-cell population with clonal markers in a subset of patients with "idiopathic" anaphylaxis. *Blood* 2007;110:2331-3.
- Teodosio C, Mayado A, Sánchez-Muñoz L, et al. The immunophenotype of

- mast cells and its utility in the diagnostic work-up of systemic mastocytosis. *J Leukoc Biol* 2015;97:49-59.
35. Zanotti R, Lombardo C, Passalacqua G, et al. Clonal mast cell disorders in patients with severe Hymenoptera venom allergy and normal serum tryptase levels. *J Allergy Clin Immunol* 2015 January 17 (Epub ahead of print).
36. Valent P, Horny HP, Escribano L, et al. Diagnostic criteria and classification of mastocytosis: a consensus proposal. *Leuk Res* 2001;25:603-25.
37. Cohen SS, Skovbo S, Vestergaard H, et al. Epidemiology of systemic mastocytosis in Denmark. *Br J Haematol* 2014;166:521-8.
38. Castells M, Metcalfe DD, Escribano L. Diagnosis and treatment of cutaneous mastocytosis in children: practical recommendations. *Am J Clin Dermatol* 2011;12:259-70.
39. Valent P, Akin C, Escribano L, et al. Standards and standardization in mastocytosis: consensus statements on diagnostics, treatment recommendations and response criteria. *Eur J Clin Invest* 2007;37:435-53.
40. Carter MC, Metcalfe DD, Clark AS, Wayne AS, Maric I. Abnormal bone marrow histopathology in paediatric mastocytosis. *Br J Haematol* 2015;168:865-73.
41. Bodemer C, Hermine O, Palmérini F, et al. Pediatric mastocytosis is a clonal disease associated with D816V and other activating c-KIT mutations. *J Invest Dermatol* 2010;130:804-15.
42. Alvarez-Twose I, Vañó-Galván S, Sánchez-Muñoz L, et al. Increased serum baseline tryptase levels and extensive skin involvement are predictors for the severity of mast cell activation episodes in children with mastocytosis. *Allergy* 2012;67:813-21.
43. Lim KH, Tefferi A, Lasho TL, et al. Systemic mastocytosis in 342 consecutive adults: survival studies and prognostic factors. *Blood* 2009;113:5727-36.
44. Erben P, Schwaab J, Metzgeroth G, et al. The KIT D816V expressed allele burden for diagnosis and disease monitoring of systemic mastocytosis. *Ann Hematol* 2014;93:81-8.
45. Hoermann G, Gleixner KV, Dinu GE, et al. The KIT D816V allele burden predicts survival in patients with mastocytosis and correlates with the WHO type of the disease. *Allergy* 2014;69:810-3.
46. Yavuz AS, Lipsky PE, Yavuz S, Metcalfe DD, Akin C. Evidence for the involvement of a hematopoietic progenitor cell in systemic mastocytosis from single-cell analysis of mutations in the c-kit gene. *Blood* 2002;100:661-5.
47. Escribano L, Alvarez-Twose I, Sánchez-Muñoz L, et al. Prognosis in adult indolent systemic mastocytosis: a long-term study of the Spanish Network on Mastocytosis in a series of 145 patients. *J Allergy Clin Immunol* 2009;124:514-21.
48. Wheatley LM, Togias A. Allergic rhinitis. *N Engl J Med* 2015;372:456-63.
49. Schwartz LB, Metcalfe DD, Miller JS, Earl H, Sullivan T. Tryptase levels as an indicator of mast-cell activation in systemic anaphylaxis and mastocytosis. *N Engl J Med* 1987;316:1622-6.
50. Ravi A, Butterfield A, Weiler CR. Mast cell activation syndrome: improved identification by combined determinations of serum tryptase and 24-hour urine 11 β -prostaglandin2 α . *J Allergy Clin Immunol Pract* 2014;2:775-8.
51. Akin C, Valent P, Metcalfe DD. Mast cell activation syndrome: proposed diagnostic criteria. *J Allergy Clin Immunol* 2010;126(6):1099.e4-1104.e4.
52. Valent P, Akin C, Arock M, et al. Definitions, criteria and global classification of mast cell disorders with special reference to mast cell activation syndromes: a consensus proposal. *Int Arch Allergy Immunol* 2012;157:215-25.
53. Sonneck K, Florian S, Müllauer L, et al. Diagnostic and subdiagnostic accumulation of mast cells in the bone marrow of patients with anaphylaxis: monoclonal mast cell activation syndrome. *Int Arch Allergy Immunol* 2007;142:158-64.
54. Ribatti D. Mast cells as therapeutic target in cancer. *Eur J Pharmacol* 2015 Apr 24. (Epub ahead of print).
55. Schwartz LB. Diagnostic value of tryptase in anaphylaxis and mastocytosis. *Immunol Allergy Clin North Am* 2006;26:451-63.
56. Kristensen T, Vestergaard H, Møller MB. Improved detection of the KIT D816V mutation in patients with systemic mastocytosis using a quantitative and highly sensitive real-time qPCR assay. *J Mol Diagn* 2011;13:180-8.
57. Lieberman P, Nicklas RA, Oppenheimer J, et al. The diagnosis and management of anaphylaxis practice parameter: 2010 update. *J Allergy Clin Immunol* 2010;126(3):477.e42-480.e42.
58. Butterfield JH. Increased leukotriene B4 excretion in systemic mastocytosis. *Prostaglandins Other Lipid Mediat* 2010;92:73-6.
59. Clemons A, Vasiadi M, Kempuraj D, Kourelis T, Vidoros G, Theoharides TC. Amitriptyline and prochlorperazine inhibit proinflammatory mediator release from human mast cells: possible relevance to chronic fatigue syndrome. *J Clin Psychopharmacol* 2011;31:385-7.
60. Godt O, Proksch E, Streit V, Christophers E. Short- and long-term effectiveness of oral and bath PUVA therapy in urticaria pigmentosa and systemic mastocytosis. *Dermatology* 1997;195:35-9.
61. Schoch C. In vitro inhibition of human conjunctival mast-cell degranulation by ketotifen. *J Ocul Pharmacol Ther* 2003;19:75-81.
62. Alevizos M, Karagkouni A, Vasiadi M, et al. Rupatadine inhibits inflammatory mediator release from human laboratory of allergic diseases 2 cultured mast cells stimulated by platelet-activating factor. *Ann Allergy Asthma Immunol* 2013;111:524-7.
63. Horan RF, Sheffer AL, Austen KF. Cromolyn sodium in the management of systemic mastocytosis. *J Allergy Clin Immunol* 1990;85:852-5.
64. Oka T, Kalesnikoff J, Starkl P, Tsai M, Galli SJ. Evidence questioning cromolyn's effectiveness and selectivity as a 'mast cell stabilizer' in mice. *Lab Invest* 2012;92:1472-82.
65. Vieira Dos Santos R, Magerl M, Martus P, et al. Topical sodium cromoglicate relieves allergen- and histamine-induced dermal pruritus. *Br J Dermatol* 2010;162:674-6.
66. Weng Z, Patel A, Panagiotidou S, Theoharides TC. The novel flavone tetrahydroxyluteolin is a potent inhibitor of human mast cells. *J Allergy Clin Immunol* 2015;135(4):1044.e5-1052.e5.
67. Maurer M, Rosén K, Hsieh HJ. Omalizumab for chronic urticaria. *N Engl J Med* 2013;368:2530.
68. Carter MC, Robyn JA, Bressler PB, Walker JC, Shapiro GG, Metcalfe DD. Omalizumab for the treatment of unprovoked anaphylaxis in patients with systemic mastocytosis. *J Allergy Clin Immunol* 2007;119:1550-1.
69. Akin C, Fumo G, Yavuz AS, Lipsky PE, Neckers L, Metcalfe DD. A novel form of mastocytosis associated with a transmembrane c-kit mutation and response to imatinib. *Blood* 2004;103:3222-5.
70. Krauth MT, Mirkina I, Herrmann H, Baumgartner C, Kneidinger M, Valent P. Midostaurin (PKC412) inhibits immunoglobulin E-dependent activation and mediator release in human blood basophils and mast cells. *Clin Exp Allergy* 2009;39:1711-20.
71. Shah NP, Lee FY, Luo R, Jiang Y, Donker M, Akin C. Dasatinib (BMS-354825) inhibits KITD816V, an imatinib-resistant activating mutation that triggers neoplastic growth in most patients with systemic mastocytosis. *Blood* 2006;108:286-91.
72. Kluin-Nelemans HC, Oldhoff JM, Van Doormaal JJ, et al. Cladribine therapy for systemic mastocytosis. *Blood* 2003;102:4270-6.
73. Pardnani A, Hoffbrand AV, Butterfield JH, Tefferi A. Treatment of systemic mast cell disease with 2-chlorodeoxyadenosine. *Leuk Res* 2004;28:127-31.
74. Ustun C, Reiter A, Scott BL, et al. Hematopoietic stem-cell transplantation for advanced systemic mastocytosis. *J Clin Oncol* 2014;32:3264-74.
75. Harvima IT, Levi-Schaffer F, Draber P, et al. Molecular targets on mast cells and basophils for novel therapies. *J Allergy Clin Immunol* 2014;134:530-44.

Copyright © 2015 Massachusetts Medical Society.

Supplementary Appendix

This appendix has been provided by the authors to give readers additional information about their work.

Supplement to: Theoharides TC, Valent P, Akin C. Mast cells, mastocytosis, and related disorders. *N Engl J Med* 2015;373:163-72. DOI: 10.1056/NEJMra1409760

<i>Table of Contents</i>	<i>page</i>
Figures	
Figure S1	2
Figure S2	3
Tables	
Table S1	4

Figure S1

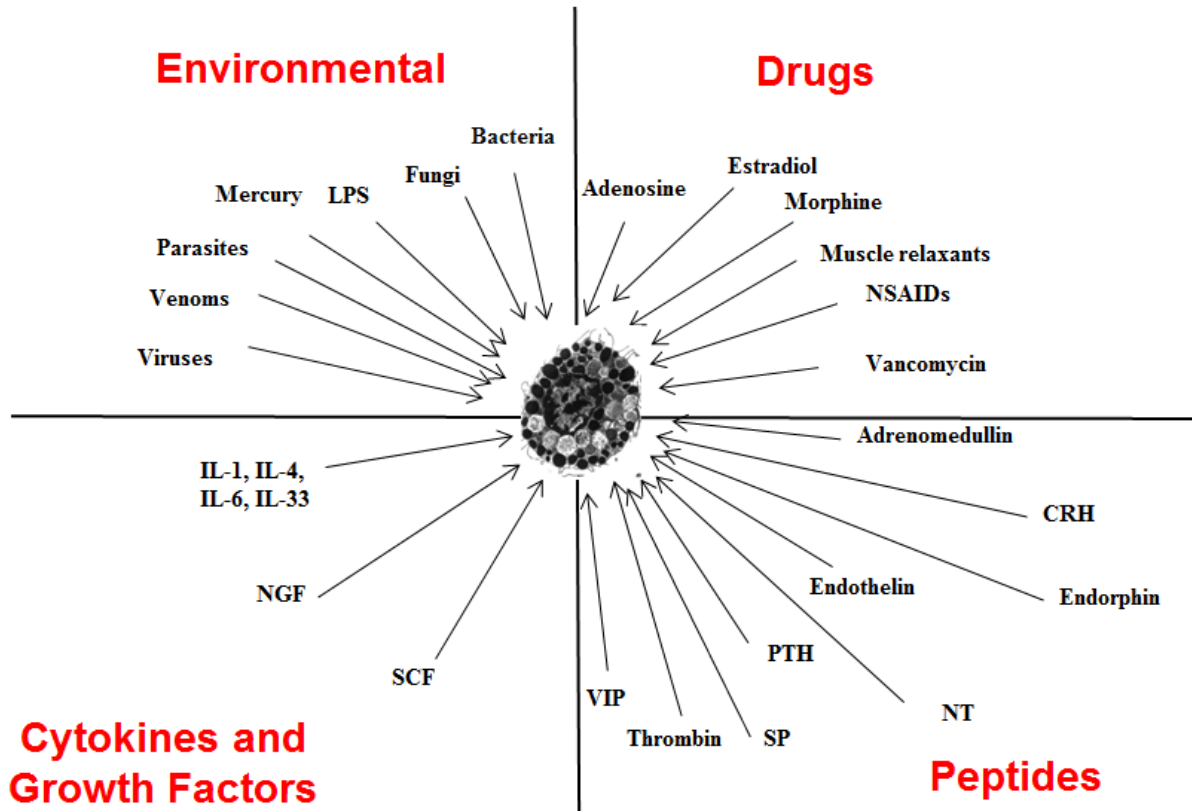


Figure S1. Mast Cell Triggers.

Diagram highlighting the most clinically relevant triggers of mast cells.

Figure S2

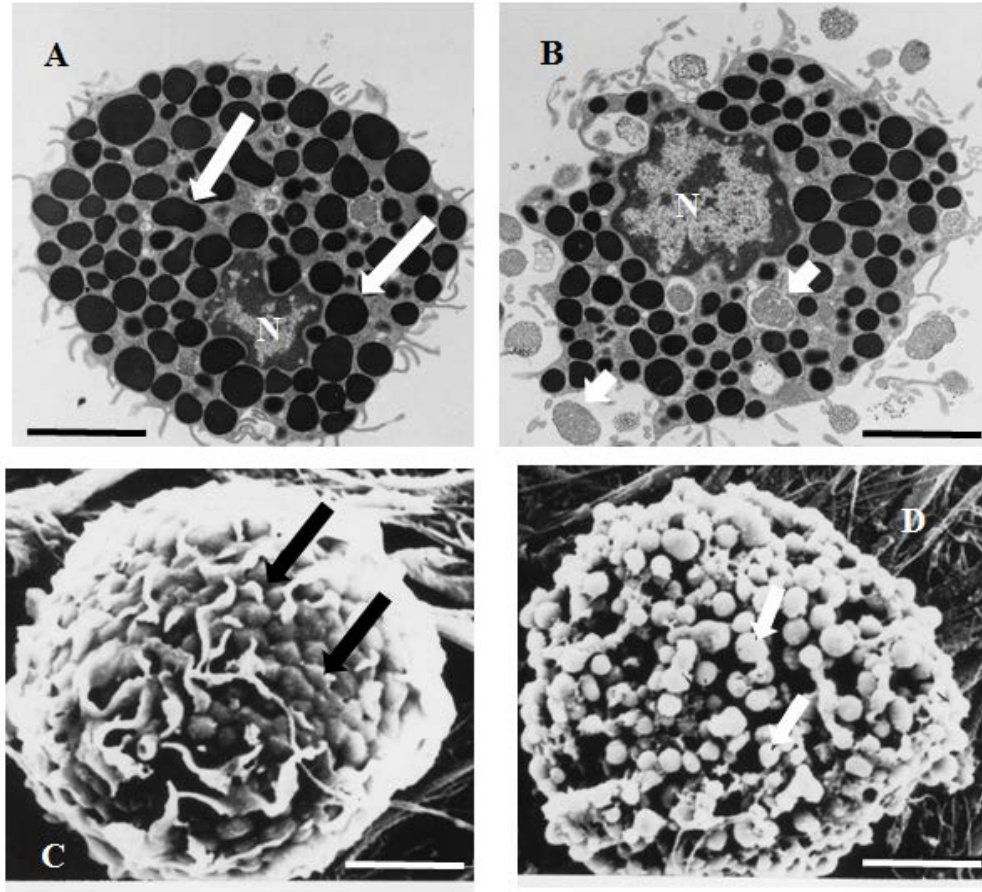


Figure S2. Mast Cell Degranulation.

Transmission (A, B) and scanning (C, D) electron photomicrographs showing one intact (A,C) and one degranulated (B,D) mast cell. Arrows indicate secretory granules. N=nucleus. Scale bar = 5 μ m.

Table S1. Mastocytosis

- Cutaneous Mastocytosis (CM)
 - Urticaria pigmentosa (UP)
 - Diffuse cutaneous mastocytosis (DCM)
 - Mastocytoma of skin

 - Systemic Mastocytosis (SM)
 - Indolent SM (ISM)
 - SM with an associated hematologic non-MC-lineage disease (SM-AHNMD)
 - Aggressive SM (ASM)
 - Mast cell leukemia (MCL)
-

In order to view the video, you MUST access this article through

www.NEJM.org or www.pubmed.gov